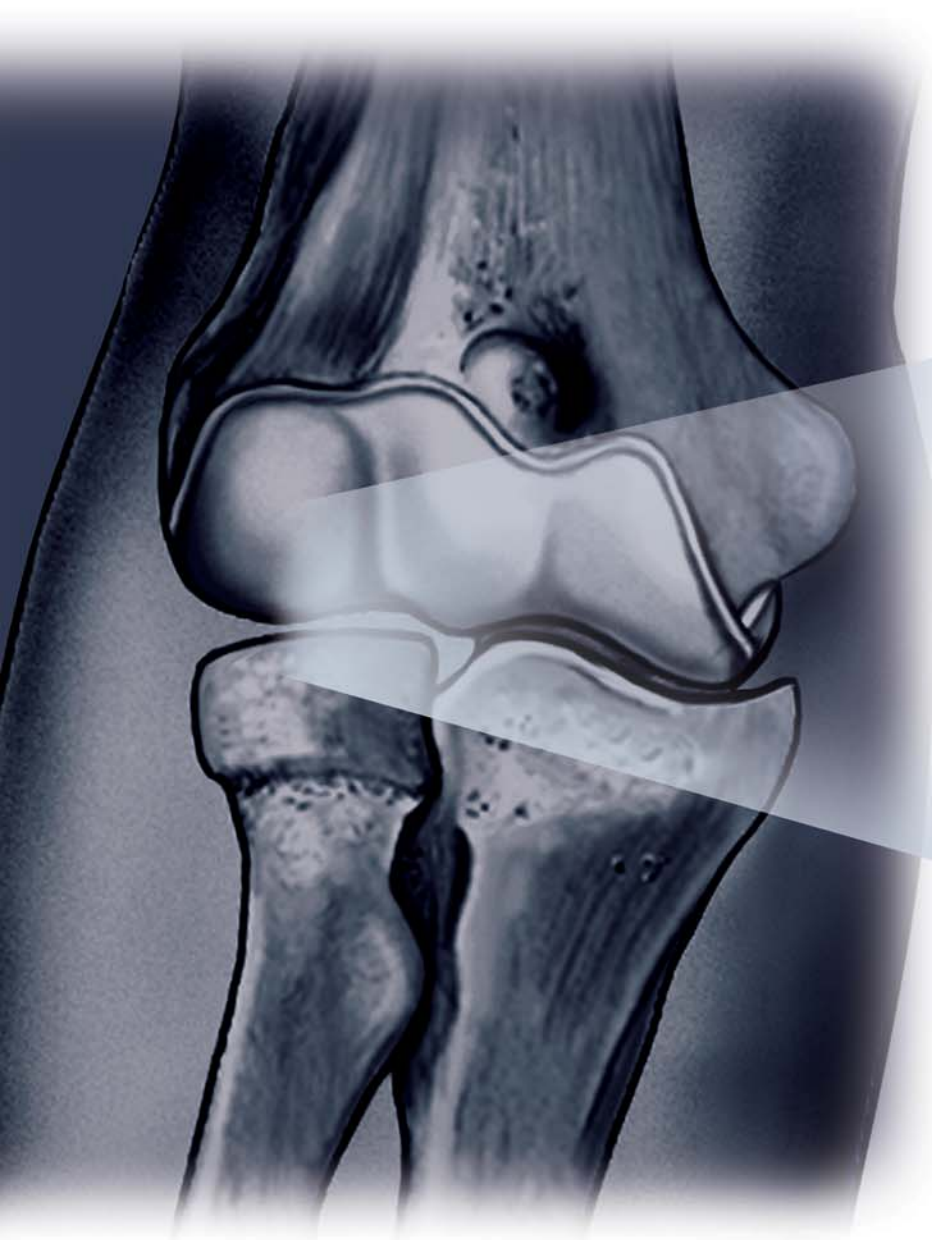


SURGICAL TECHNIQUE

UNI-ELBOW *PGT*TM
RADIO CAPITELLUM SYSTEM
*WITH PRECISE
GUIDANCE TECHNOLOGY*



SBi
SMALL BONE INNOVATIONS

SURGICAL TECHNIQUE

1 Incision

The patient is placed under a general or a regional anesthesia. The extremity is prepped and draped in the usual sterile fashion. A sterile tourniquet is often a good option. An arm table may be used if the patient is in a supine position or the arm may be brought across the chest.

A classic Kocher skin incision is made identifying the interval between the anconeus and the extensor carpi ulnaris. The incision extends approximately 6-7cm. The dissection is carried down to the joint capsule. The origin of the anconeus can be released subperiosteally and retracted posteriorly to permit adequate exposure of the capsule.

2 Exposure

If the elbow is stable, the capsule is exposed by elevating a portion of the extensor carpi ulnaris sufficiently to allow identification of the lateral collateral ligament complex. Alternatively, the extensor carpi ulnaris may be split longitudinally in line with its fibers staying anterior to the attachment of the lateral collateral ligament. The lateral capsule is divided slightly anteriorly to the collateral ligament and the annular ligament and capsule are reflected anteriorly and posteriorly to expose the radial head. A portion of the lateral collateral ligament and anterior capsule can be reflected off the lateral epicondyle and anterior humerus to expose the capitellum. The lateral ulno-humeral ligament must not be disturbed. If the ligament has been disrupted, then the exposure progresses through the site of disruption to expose the radiohumeral joint. The common extensor tendon and elbow joint capsule are retracted as needed to maximize exposure (FIGURE 1).

3 Axis of Rotation Locator Clamp Assembly and K-wire Placement

Assemble the Axis of Rotation Locator Clamp by securing the Locator Cup with the Cup Bolt and Upper Arm to the Axis Bar Slot Bolt. Then assemble the Drill Guide to the Upper Arm and advance the thread half way down. There are two Capitellum Templates in the instrument set, left and right. Each end of the Template is labeled to match the large or small implant. Preoperative planning with the x-ray template is recommended to assist in the selection of the appropriate sized implant. Place the center hole of the Capitellum Template under the Drill Guide and advance the Template until it engages the retaining ring (FIGURE 2).

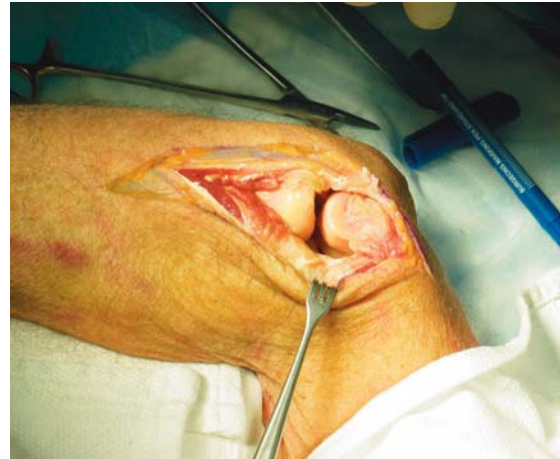

FIGURE 1

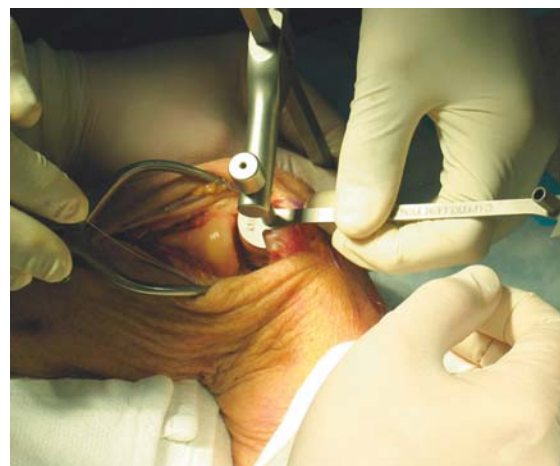

FIGURE 2

Small Bone Innovations does not recommend a particular surgical technique when using the implant. Proper surgical procedures and techniques are the responsibility of the medical professional. Each surgeon must evaluate the appropriateness of the surgical technique used based on personal medical training and experience.

Caution: United States federal law restricts this device to sale by or on the order of a physician.

The Axis of Rotation Locator Clamp is then placed over the elbow with the medial epicondyle resting in the Locator Cup. Match the outline of the template with the distal articulating surface of the capitellum. The curvature of the edge of the template should align with the most distal articular surface of the original capitellum. Once alignment is achieved, tighten the Drill Guide against the lateral epicondyle. Insert a .062 K-wire through the Drill Guide and advance into the capitellum. The K-wire should be advanced to the mid-line of the distal humerus when viewed on the P/A plane. Care should be taken not to extend the K-wire through the medial epicondyle. Leaving the K-wire in place, remove the Axis of Rotation Locator Clamp and Template (**FIGURE 3**).

4 **PGT™ Resection Guide**

There are two Resection Guides, Small and Large. Based on Capitellum Template being used, choose the corresponding Resection Guide. Place the PGT Resection Guide over the K-wire and slide down until it rests on the capitellum. Assemble the Resection Guide Handle to the Resection Guide and align so it is parallel with the long axis of the humerus. Once proper alignment is achieved, place the second .062 K-wire in the Resection Guide to secure the orientation. The handle can then be removed. The PGT Resection Guide has two slots for resection of the capitellum. The proximal, or posterior, slots represent the actual size of the capitellum implant. The distal, or anterior, slots are off-set by 2mm and would be used when excessive erosion of the capitellum is present. Either both proximal or both distal slots must be used. Mis-matched cutting guide slots cannot be used.

Using a sagittal saw, insert the sawblade into the chosen slot in the resection guide. Perform the transverse and oblique cuts to the deep base of the capitellum.

IMPORTANT: The cut should never cross the ridge of the trochlea. Using a small osteotome and rongeur, remove the capitellar head and trim remaining fragments (**FIGURES 4 AND 5**).

5 **Capitellum Trial**

Assemble the Capitellum Trial Handle onto the Capitellum Trial. Place the Capitellum Trial against the resected humerus. Insert .062 K-wires through the lateral holes and into the distal humerus to firmly secure the trial component. Remove the Trial Handle and crop the K-wires at the surface of the trial leaving enough K-wire exposed to facilitate removal but not allowing the K-wire to make contact with the radial head. Access range of motion (**FIGURE 6**).

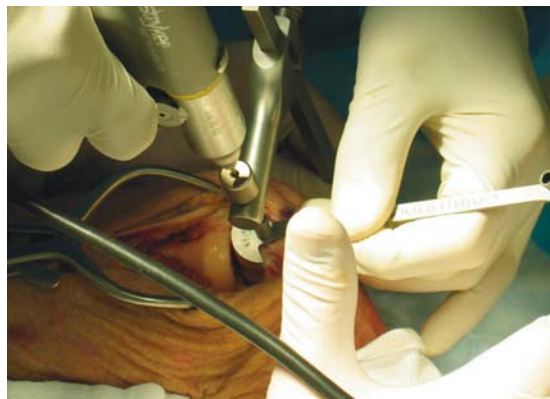


FIGURE 3

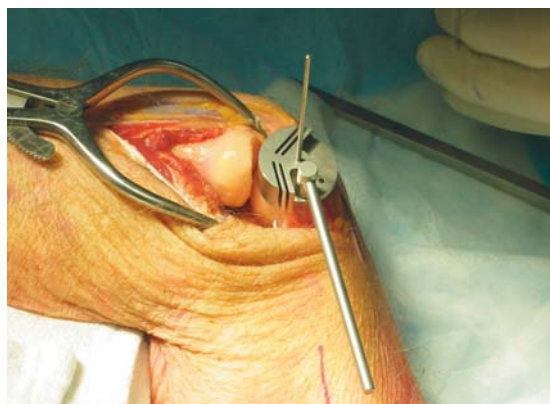

FIGURE 4

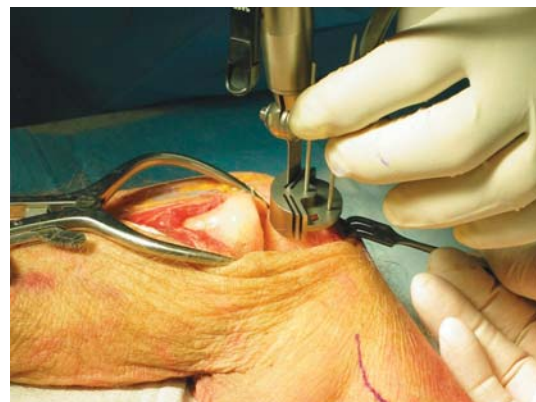

FIGURE 5

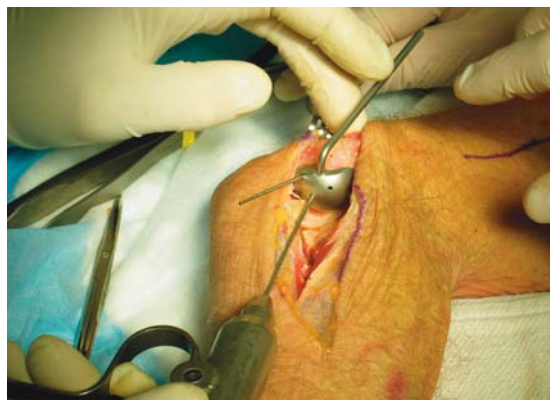

FIGURE 6

6 Radial Head Resection

The radial neck cut requires the rHead™ Resection Guide. This instrument is used to identify the anatomic axis of forearm rotation. Adjust the Capitellum Flange of the Resection Guide to correspond to the appropriate head size which was preoperatively determined. Place the proximal flange of the axis guide against the articular surface of the capitellum trial and align the distal rod with the ulnar styloid. Test forearm rotation with the axis guide in place to ensure proper alignment.

During the resection, the forearm is pronated and supinated while the cutting guide is used to align the sawblade perpendicular to the axis of rotation defined by the resection guide. The extent of resection is the minimal amount that is consistent with the restoration of function as dictated by the fracture line or previous radial head resection. This includes at least the margin articulating with the ulna at the radial notch. In addition, radial length must be restored using a lamina spreader (axial traction) if there is a positive ulna variance (**FIGURE 7**).

7 Broaching of the Radius

If the elbow is unstable, varus stress and rotation of the forearm into supination allows improved access to the medullary canal. If the elbow is stable but the exposure is not adequate to access the medullary canal, careful reflection of the origin of the collateral ligament from the lateral epicondyle may be necessary to permit subluxation to the medullary canal. The canal is broached taking care to identify the proper axial orientation. The forearm should be in mid-rotation with the tuberosity directed medially. This position is favorable for broaching and implantation as the curve of the broach/implant points lateral or away from the radial tuberosity. Serial sized broaches are used until the broach fits firmly in the canal to the appropriate depth (**FIGURE 8**).

8 Trial Reduction, Proximal Radius

The trial stem corresponding to the broach used to prepare the canal is inserted and impacted. Assure the stem's collar is flush with the resected head. The trial radial head component is then assembled to the trial stem and the joint is reduced. Tracking, both in flexion and extension and forearm rotation should be carefully assessed. Mal-alignment of the radial osteotomy will cause abnormal tracking during flexion-extension and/or forearm pronation and supination. Remove the radial head and stem trials if tracking and alignment is satisfactory (**FIGURE 9**).

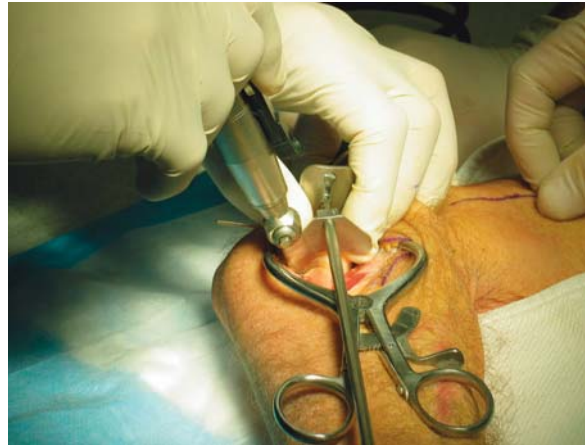

FIGURE 7

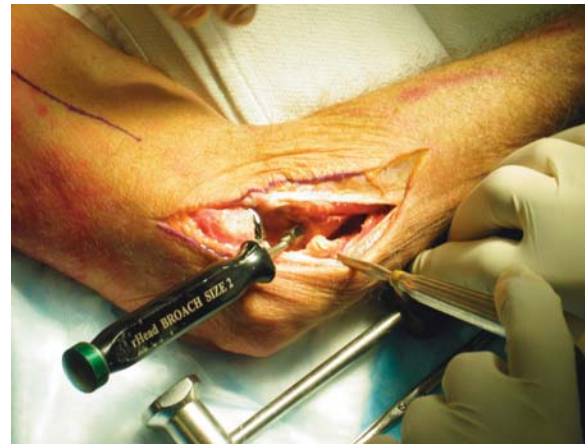

FIGURE 8

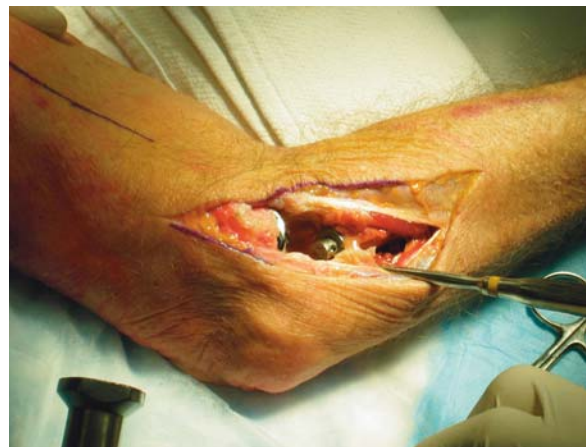

FIGURE 9

9 Broaching of the Distal Humerus

Insert .062 K-wire into the center hole of the capitellum trial. Advance the K-wire into the distal humerus but do not extend beyond the posterior cortex. The center K-wire will act as the broach guide wire. Remove the lateral K-wires and slide the capitellum trial off the center K-wire. The elbow may have to be brought into full flexion to remove the trial. Using the cannulated 3.5mm drill, drill over the center K-wire to create the broach pilot hole into the distal humerus. Care should be taken not to over drill or perforate the posterior cortex of the humerus. Insert broach into the pilot hole and impact. The broach should be advanced until the teeth are at the same level as the capitellum osteotomy. Care should be taken to identify proper alignment and not to over broach the distal humerus (FIGURES 10 AND 11).

10 Implanting the Final Components

Once broaching is complete, the definitive implant can be inserted. Distraction of the proximal radius as well as flexion of the elbow may be necessary to allow sufficient access for capitellum insertion. Insert the capitellar stem into the canal and tap into place using the impactor. Bone cement (PMMA) is indicated for the capitellar component (FIGURE 12).

Insert the radial stem down the canal of the proximal radius and tap into place with the impactor. Care should be taken to protect the articulating surface of the implant at all times. The modular head is placed over the taper using longitudinal distraction and/or varus stress to distract the radio capitellum interface sufficiently to permit the radial head to be inserted. Once inserted, the radial head is secured using the impactor. The elbow is then reduced and tested again in flexion/extension and pronation/supination (FIGURE 13).

11 Closure

A simple closure is permitted if the collateral ligament is not disrupted. If the collateral ligament has been disrupted, a Krakow stitch is used in the substance of the lateral ulnar collateral ligament. A No. 5 absorbable suture is placed distally, crosses the site of the lateral ulnar collateral ligament and then brought proximally. Both ends of the suture are brought through a drill hole at the anatomic origin of the lateral collateral ligament complex and exit posteriorly. The forearm is placed in full or partial rotation and the suture tied. The elbow is splinted at 90 degrees flexion and in neutral to full pronation.

12 Aftercare

Passive flexion and extension is allowed on the second day assuming the elbow is considered stable. The goal of radial head replacement and soft tissue repair is to achieve elbow stability. Both flexion/extension and pronation/supination arcs are allowed without restriction. Active motion can begin by day five. Long term aftercare requires surveillance as with any prosthetic replacement. If the implant is asymptomatic and tracks well, routine removal is not necessary.

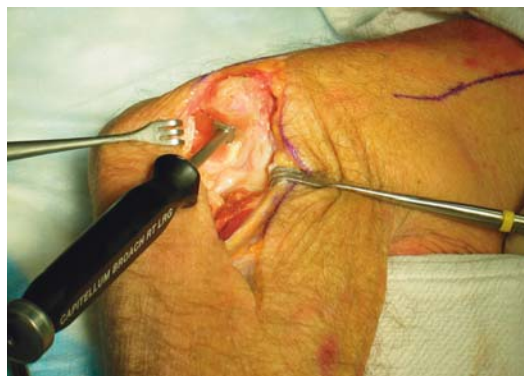

FIGURE 10

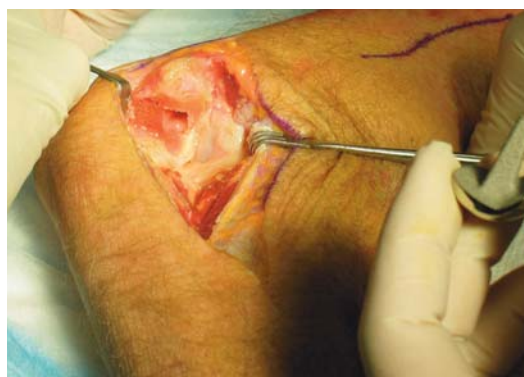

FIGURE 11

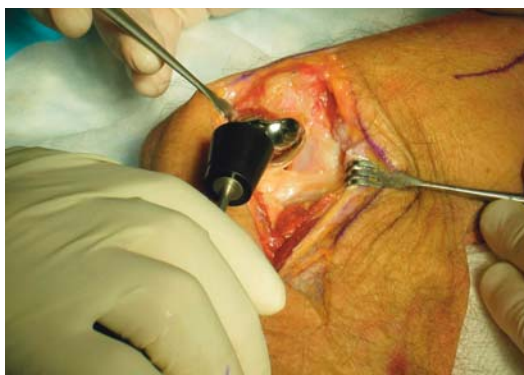

FIGURE 12

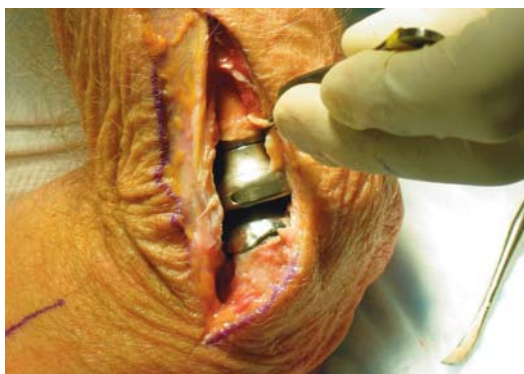

FIGURE 13

Small Bone Innovations, Inc.

SBi Customer Service: (800) 778-8837

1380 South Pennsylvania Ave.

Morrisville, PA 19067

Fax (215) 428-1795

Technical Support: (866) SBI-TIPS

www.totalsmallbone.com

Small Bone Innovations International

ZA Les Bruyères - BP 28

01960 Péronnas, France

Tel: +33 (0) 474 21 58 19

Fax: +33 (0) 474 21 43 12

info@sbi-intl.com